



SYNDROME GOUGEROT-SJOGREN COMPLICATED OF LYMPHOMA MALT parotid: ABOUT A CASE.

Mohamed MLIHA TOUATI *, Youssef DAROUASSI, Mehdi CHIHANI, Brahim BOUAITY,
Haddou AAMAR(1).

ENT department, Military Hospital Avicenna, Marrakech, Morocco.

ABSTRACT

Lymphoproliferative syndrome is a serious and dangerous complication during sicca Sjogren's syndrome, the risk of occurrence is 40 times higher during this connectiviteque the general population. Lymphoma can be found at any stage in the evolution Gougerot Sjögren's syndrome. We report a case illustrating the unusual revelation lymphoma during diagnosis Sjogren Sjögren's syndrome.

Keyword : MALT lymphoma, parotid gland, Sjogren Sjögren.

INTRODUCTION

Sicca Sjogren's syndrome (SGS) is an autoimmune épithélite exocrine glands which may be complicated by lymphoproliferative syndrome [1]. The association with MALT lymphoma is less common. We report a patient followed for a complicated pSS a MALT lymphoma of the parotid gland. [1]

MATERIALS AND METHODS

CLINICAL CASE

Patient of 68 years, hypertensive for 10 years, complicated by kidney failure. Followed for 5 years for a syndrome of SMS corticosteroids. Present for 1 month bilateral parotidomégalie, operating in a context of asthenia, anorexia and weight loss, fever and night sweats.

Clinical examination found bilateral parotid swelling, cervical lymph nodes, submandibular and bilateral inguinal. Abdominal examination found moderate splenomegaly. Laboratory tests revealed an inflammatory syndrome, CRP 36mg / L, erythrocyte sedimentation rate of 60 mm the first hour. The protein electrophoresis is a monoclonal peak at gamma globulin. B2 microglobulin to 2,83ng / l. the creatinine clearance to 21.06 ml / min. The scanner of the parotid glands (figureN1) is a parotid tissue hypertrophy, multi cystic predominant bilateral left with satellite nodes and latero-cervical bilateral high.

Parotid biopsy found a compatible look with MALT lymphoma of low grade malignant salivary

gland (Figure N 2). The immunolabeling directed shows a positive interstitial cells to antiCD20 antibodies, CD3, a positive lymphocytes realizing exocytosis at the epi-myoeptithelial complex and medium sized cells antiCD20 antibodies. The bone marrow biopsy shows lymphoma proliferation.

The treatment consisted of chemotherapy base (cyclophosphamide, vincristine, doxorubicin, methylprednisolone). The doses were adapted according to the creatinine clearance. The evolution was rapidly favorable with disappearance of swelling and improvement in general health.

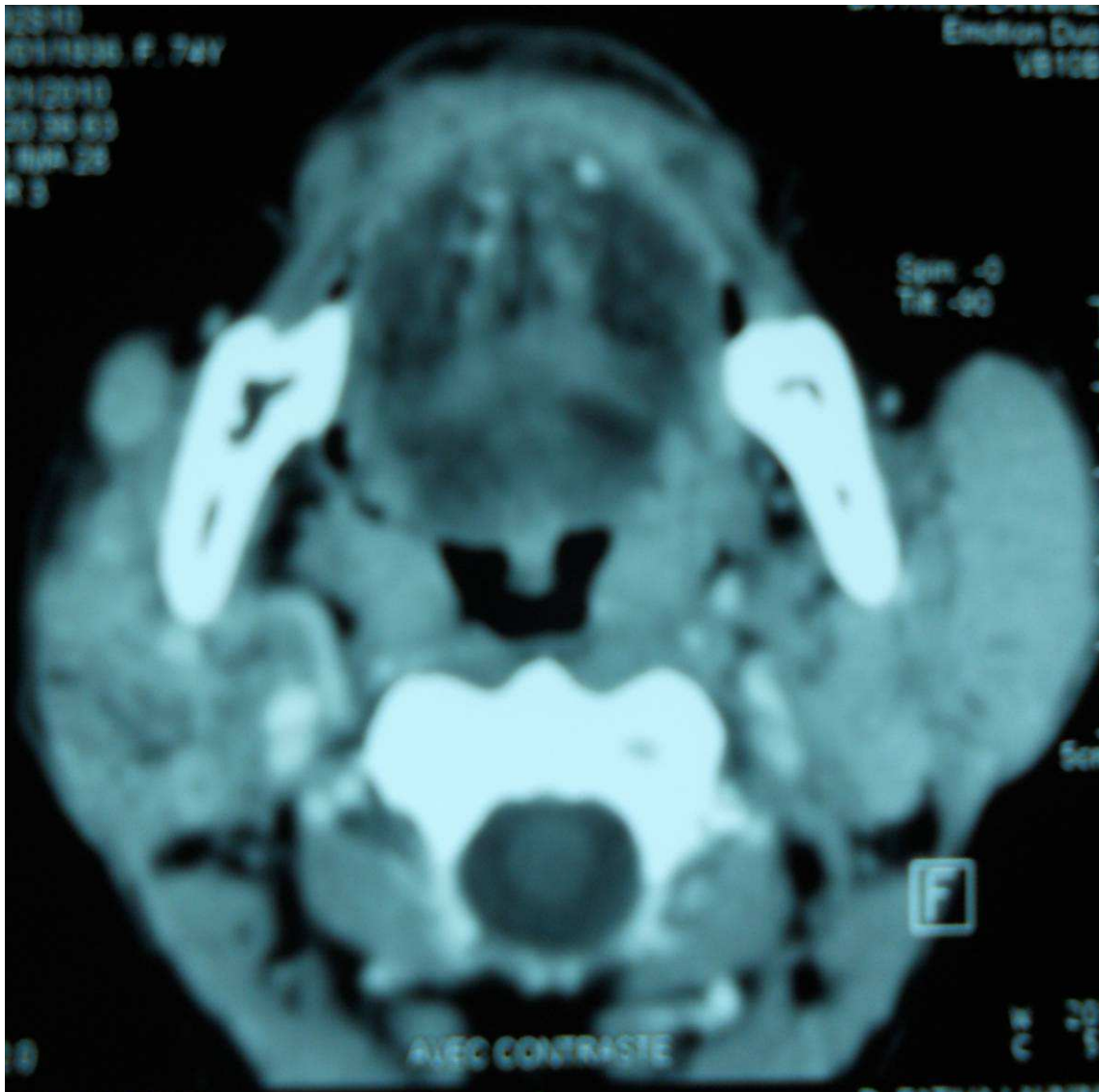

Figure 1: Cross section showing the parotidomegalie.

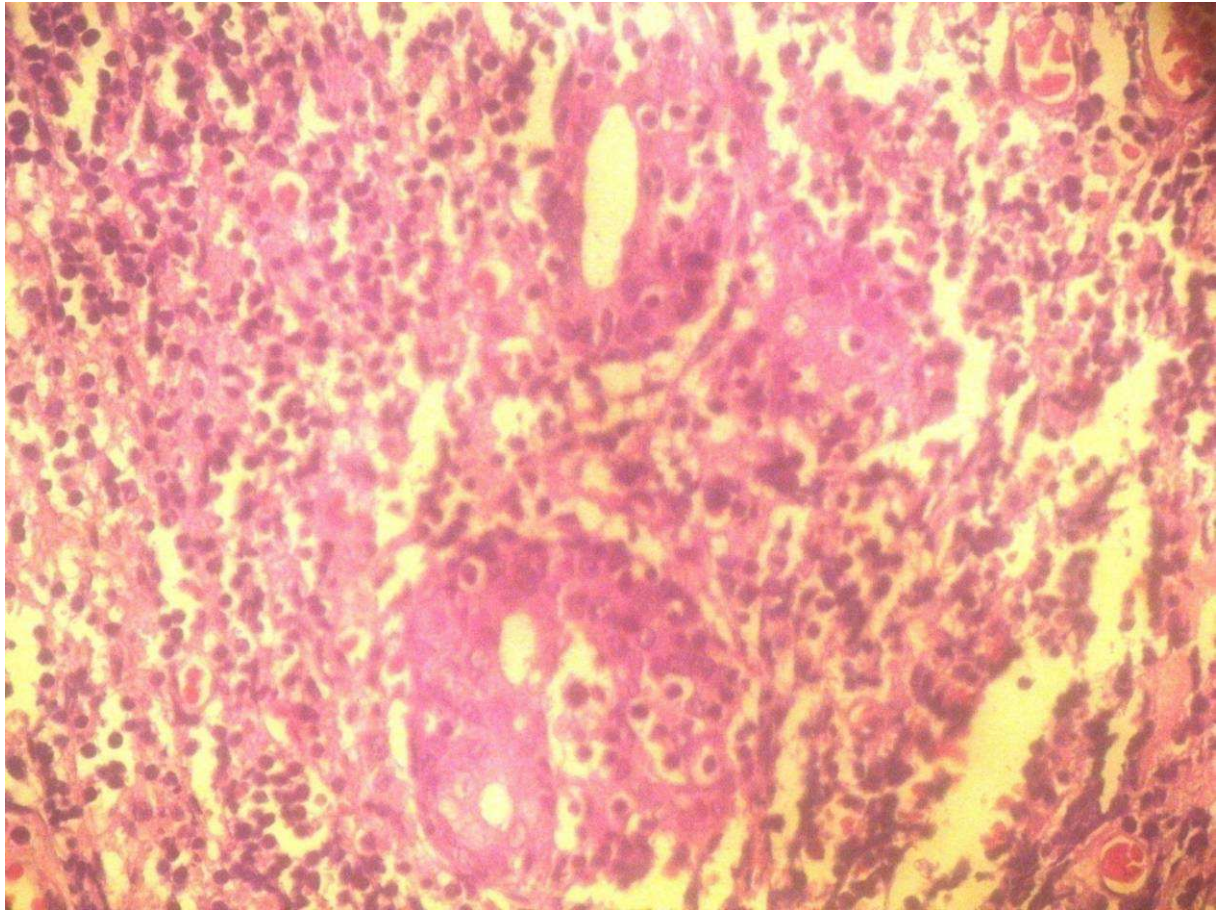


Figure 2: (E x 200) lymphocytic infiltrate realizing exocytosis in the parotid glands.

RESULT AND DISCUSSION

The risk of occurrence of non-Hodgkin's lymphoma (NHL) in patients with primary SGS is known. A recent study by Swedish Theander et al. [1-2] found an incidence of NHL nearly 16 times that of the general population in a cohort of 507 patients followed for an average of eight years. On the other hand, the risk of NHL increases with time, ie more are diagnosed long more the risk increases. It is thus 6.4% in the first five years of the disease, 11.1% between the 6th and the 11th year and 20.8% between the 10th and 15th year in the Swedish cohort. In our patient the period is 5 years. Diagnosis is based on clinical: The appearance of a parotidomégalie, splenomegaly or lymphadenopathy (as is the case of our patient). Palpable purpura or skin ulcers. The appearance of symptoms (night sweats, unexplained prolonged fever, weight loss ...). It is mainly the biological markers that caught the attention of the authors. It was suggested that the appearance of a monoclonal immunoglobulin, or rather the disappearance of IgM, the appearance of free light chains in urine or significant elevation of beta-2-microglobulin were elements announcing the development of lymphoma [3-4] .L'histologie confirms the diagnosis of lymphoma and immunohistochemical specifies the type [5]. The prognosis depends on the type of lymphoma and tumor extension. [6,7] The treatment is based on chemotherapy and radiotherapy. The drug therapy may be recommended when the lymphoma is indolent. [8]

CONCLUSION

The MALT lymphoma complicating SGS is a rare disease, diagnosis is called to the clinic, biology and CT. Histology confirmed the diagnosis and specify the type of lymphoma that affects the

subsequent management. The search for risk factor leading to malignant transformation that will enable better monitoring and that early and adequate care.

REFERENCES

- [1] Theander E, Henriksson G, Ljungberg O, Mandl T, Manthorpe R, Jacobsson L. Lymphoma and other malignancies in primary Sjogren's syndrome: a cohort study on cancer incidence and lymphoma predictors. *Ann Rheum Dis*, **2006**,65,796–803.
- [2] Saint-Marcoux.B; De Bandt.M. Syndrome de Gougerot-Sjögren : critères de classification, lymphomes, traitements. *Rev de Rhum* **2007** ,74 ,737-744.
- [3] Voulgarelis.M; Dafni.UG; Isenberg.DA; Moutsopoulos.HM. Malignant lymphoma in primary Sjogren's syndrome: a multicenter, retrospective, clinical study by the European Concerted Action on Sjogren's syndrome. *Arthritis Rheum* **1999**,42,1765-72.
- [4] Anaya JM ; Mc Guff Hs ; Banks PM; Talal N.Clinicopathological factors relating malignant lymphoma with Sjögren's Syndrome. *Semin Arthritis Rhum* **1996**,25,337-46.
- [5] Talal N, Sokoloff L, Barth WF. Extrasalivary lymphoid abnormalities in Sjogren's syndrome (reticulum cell sarcoma, "pseudolymphoma," macroglobulinemia). *Am J Med* **1967**,43,50–65.
- [6] Ioannidis JP, Vassiliou VA, Moutsopoulos HM. Long-term risk of mortality and lymphoproliferative disease and predictive classification of primary Sjogren's syndrome. *Arthritis Rheum* **2002**,46,741–7.
- [7] Grosbois.B; Jego.P; Leblay.R. Syndrome de Gougerot-Sjögren et syndromes lymphoprolifératifs malins *Rev Med Interne* **1998** ,19 , 3 19-24.
- [8] Gottenberg JE, Aucouturier F, Goetz J, Sordet C, Jahn I, Busson M, et al. Serum immunoglobulin free light chain assessment in rheumatoid arthritis and primary Sjögren's syndrome. *Ann Rheum Dis* **2007**,66,23–7.