



## ACCIDENTAL INGESTION OF BATTERIES IN CHILDREN

D. TRAORE\*, I. YARO, K. FOURAIJI, M. EE. KAMILI, M. OULAD SAIAD

*General Pediatric Surgery Department, University Hospital Mohamed VI, Marrakech*

---

### INTRODUCTION

Accidental ingestion of batteries in children is strong resurgence due to their use in products that are available to children. The electric battery is not a foreign body like the others, two specific injury mechanisms are involved, firstly burns due to electrolysis, the other by the release of toxic chemicals.

The Interest of this study is to educate on the toxicity caused by batteries.

### MATERIAL AND METHODS

Retrospective Studies from 2008 to 2016, we collected 6 cases.

### RESULT AND DISCUSSION

The age of patients was between 2 years and 4 years, 4 boy and 2 girls. The notion of ingesting of battery was reported by the parents of all children, they were 4 cases of button battery and 2 cases of Lithium cylindrical battery. The ingestion period of the battery ranged from 2 hours to 1 month. 2 patients were asymptomatic, hyper salivation and vomiting were reported in 2 cases, epigastric pain was noted in children who ingested the cylindrical battery, dysphagia to solids was found in children with the evolution of 1 month (fig 1). All the children had a thoracoabdominal radiography. The button battery was localized in the esophagus in 2 cases of which 1 case of esophagitis, and 1 case of stenosis, intestinal localization in 2 cases. Lithium cylindrical battery was localized in the stomach in 1 case (fig 2) and 1 case in the sigmoid. The extraction was endoscopic in 1 child with the battery level of the esophagus, laparotomy was performed in 3 cases, the esophageal - coloplasty in 1 case because of esophageal stenosis on the battery.

### DISCUSSION

Gastrointestinal lesions in contact with a battery is partially due to the terminals of this battery and electrolytic phenomena of acidic and basic compounds responsible for chemical burns. [1] The lesions due to substances in the battery, are consecutive to the opening of the battery in the gut and release its contents which are metal salts (mercury, zinc, lithium) or caustic (sodium hydroxide, potassium or ammonium chloride), these compounds are potentially highly toxic [2]. The incidence of accidental ingestion of the battery has increased with the spread and miniaturization of consumer electronics devices. These are children under 5 who are most at risk, they represent 60 to 70% of cases [2,3]. This expired by batteries from electronic toys. The severity of the clinical presentation

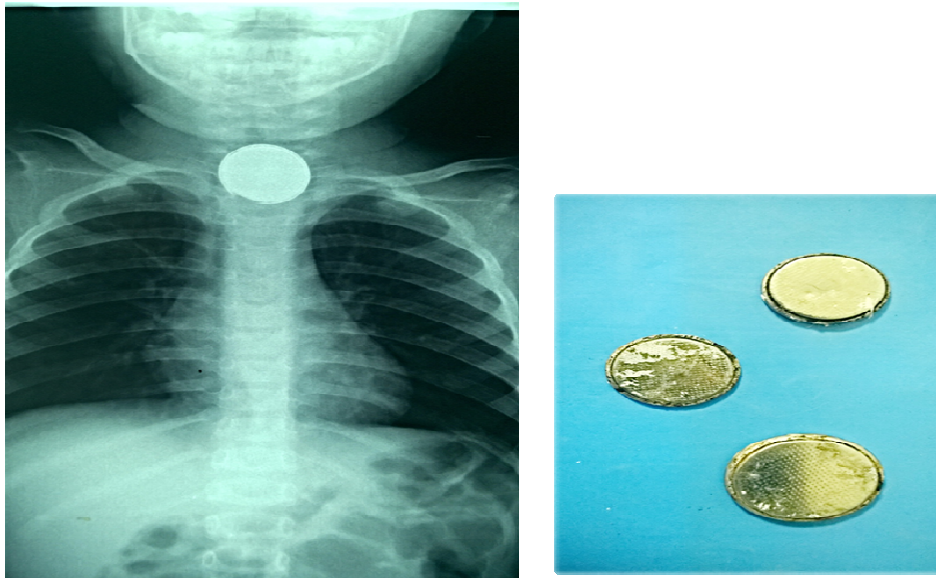ranges from the complete absence of symptoms are rare situations involving life-threatening. The complete absence of clinical signs remain the most frequent event: Ingesting the button battery can even go unnoticed and being discovered that during his appearance in the stool. Only 10% of 20 patients have symptoms, usually digestive and sometimes systemic. [3,4] .Abdominal or chest pain exists in about a third of symptomatic cases. An early onset dysphie directed immediately towards oesopgagienne location. The erosive lesions may lead to more specific manifestations depending on the location of the battery, ulceration of the gastrointestinal mucosa can cause hematemesis or melena.

**To behave :**

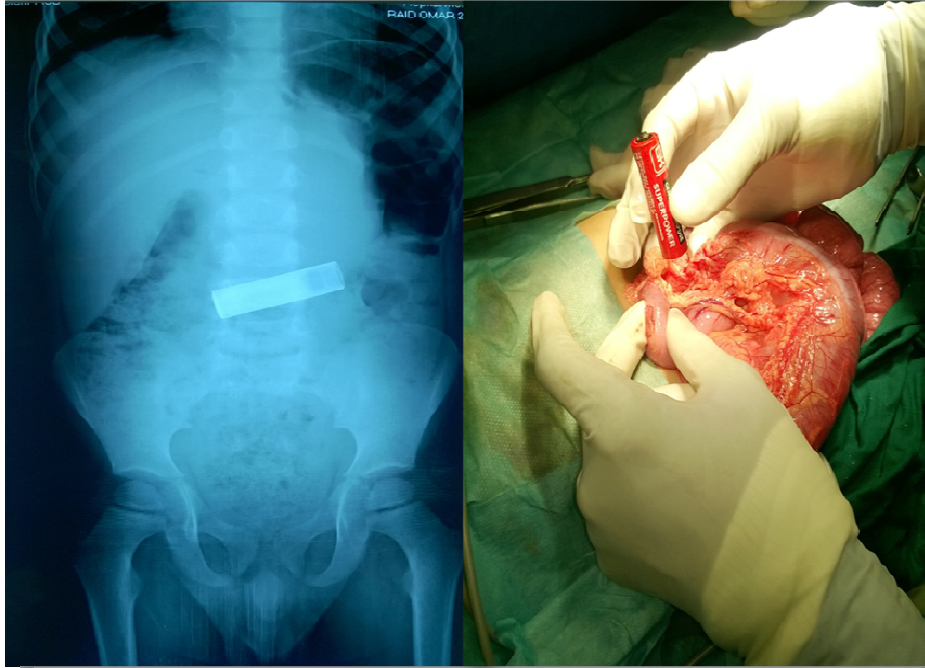
**Esophageal Location:** This location is rare, it is a therapeutic emergency because of the severity of the seriousness of these consequences such as ulceration between the 3rd and 4th hour esophageal perforation from the 6th hour, secondary scarring stenosis [2,5]. The ablation is done by endoscopy, which also allows to change the state of the lesion mucous membrane.

**Gastric Location:** What to do is more controversial. 80 to 90% of cases, the battery passes the stomach without any noticeable discomfort. The danger can come from a possible stagnation in contact with the gastric mucosa for 24-48 hours more, the acidity of secretions that can corrode the metal cap and releasing its contents. H2 antagonist therapy for lowering gastric acidity that will slow both mucosal damage and corrosion of the cell. The ablation is done by endoscopy or laparotomy.

**Intestinal Location:** The risks are low. In the absence of symptoms and signs of fragmentation of the stack, a simple clinical and radiographic monitoring was proposed by Laugel V. et al. [1] Laxative therapy may be helpful. When opening the battery, or to ulceration of clinical signs, surgery remains the only recourse. In our practice all intestinal localizations were made without waiting for signs of complications.



**Fig 1: Girl 03 years, admitted to ingestion of button battery lasting for 1 month. Esophageal stenosis on the battery. Treatment was an esophageal-coloplasty.**



**Fig 2: Boy 05 years, admitted to ingestion of cylindrical battery lasting for 24h. Surgical removal of the battery at the stomach**

### CONCLUSION

The batteries's ingestion by children is an absolute medical and surgical emergency. No diagnostic testing should not delay the treatment .

### REFERENCES

- [1] V.Laugel, J. Beladdale, B. escande, U. Simeoni. L'ingestion accidentelle de pile-bouton. Arch Pediatr **1999** ; 6 : 1231-5.
- [2] Litovitz T, Schmitz B, Ingestion of cylindrical and button batteries : an analysis of 2382 cases. Pediatrics **1992**;89:747-57.
- [3] Thompson N, Lowe-Ponsford F, Mant TKG, Volans GN. Button battery ingestion a review. Adverse Drug React Acute poisoning rev. **1990**;9:157-82.
- [4] M. Sadaoui, I. Bakhtaoui, R. Boukh et al. Ingestion des piles Bouton chez l'enfant : Experience CHU Oran. Arch Pediatr **2015** ;22 :233-371
- [5] J.Lahmar, M. Bkanchard, V. Couloigner, F. Denoyelle, E. Grabedian. Ingestion de pile bouton chez l'enfant : les dangers du multimédia. J.Aforl. **2014** ;131 : 75-103.