



## DUPLICITE DE L'ULNA OU DIMELIE ULNAIRE AVEC POLYDACTYLIE A SEPT DOIGTS A PROPOS D'UN CAS.

TRAORE Diakaridia\*, EL Mohtadi AGHOUTANE, Tarik SALAMA, Redouan EL  
FEZZAZI

Service de Orthopédie - Traumatologie Pédiatriques - Hôpital Mère-Enfant  
CHU Mohamed VI de Marrakech/MAROC

---

### ABSTRACT

*The Ulnar dimelia or Ulnar duplication is a very rare congenital anomaly of the upper limb in its classical form which combines ulna duplication, total absence of the radius and polydactyly. The complexity of treatment is related to stiffness of the elbow and wrist. The results are satisfactory aesthetically, but less functionally. We report the case of 2 year old girl with severe stiffness of the elbow, wrist and polydactyly. She is operated in 2 steps, whose relay is provided by motor rehabilitation.*

**Keywords:** Duplication – Ulna – Children

---

### INTRODUCTION

Ulnar dimella or ulnar duplication is a very rare congenital malformation of the upper limb, characterized by the duplication of the ulna with total agenesis of the radius and polydactyly. About 20 isolated cases have been reported worldwide. We present a new case with reviews of the literature.

### MATERIAL AND METHODS

This is a 2-year-old female infant admitted for congenital malformation and functional limitation of the left upper limb, diagnosed since birth.

The examination found an inequality of the length of the upper left limb about 4.7 cm, a polydactyly with 7 fingers (Fig.1), the wrist fixed in flexion at 20 °, the stiff elbow with a limitation of the flexion to 15 °, deficit of the prono-supination, the right upper limb is of normal aspect. The rest of the somatic examination is without particularity.

Standard radiograph (Fig.2) of the upper left reveals image of seven metacarpus and seven fingers triphalangian absence of the thumb, a doubling of the internal radius mirror with complete absence of the radius.

CT (Fig. 3) finds ulnar duplicity with the internal ulna, which appears to have a normal articular

surface, and the external ulna blocking the flexion of the elbow.

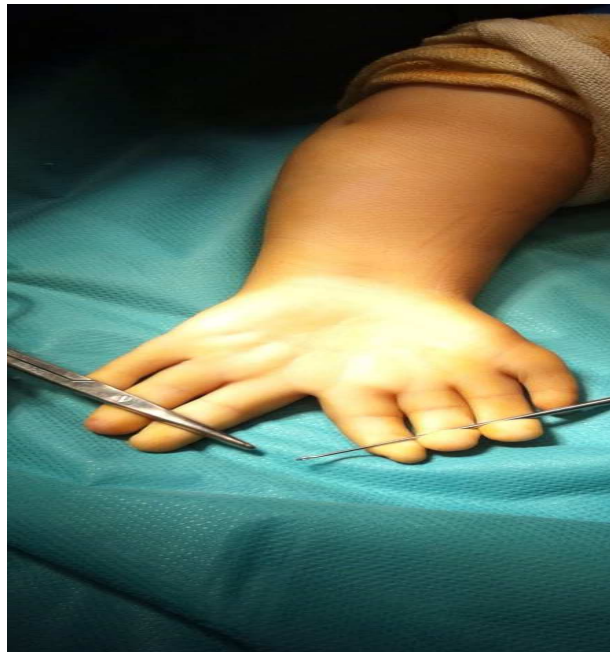
The child was operated in 2 stages:

1st time (Fig.4) dedicated to the hand. In view of the impossibility of the flexion of the 7th finger due to the interphalangeal joint malformation, its metacarpus was resected followed by the total resection of the 5th finger, the creation of an omega flap allowed to enlarge the commissure and finally the pollicization of the 6th finger.

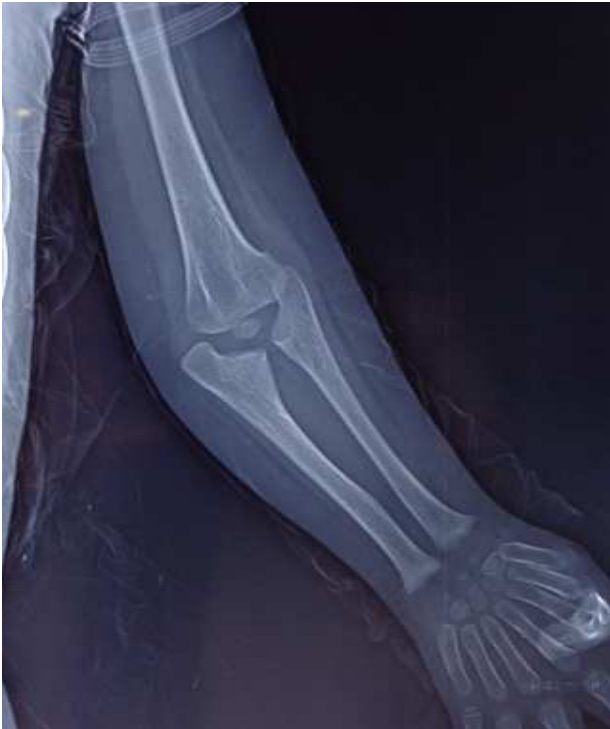2nd Time consisted of the reduction of the elbow. The exploration found an internal ulna with a small sigmoid cavity covered with cartilage, the flexion blocked by the external ulna, the resection of the upper end of it allowed to obtain a 60 ° flexion. Immobilization by a splint for 45 days.

The suites were simple, partial recovery of the bending of the elbow up to 45 °. Under rehabilitation for 7 months, we obtained a satisfactory result of thumb-index apposition with a good grip of light objects.

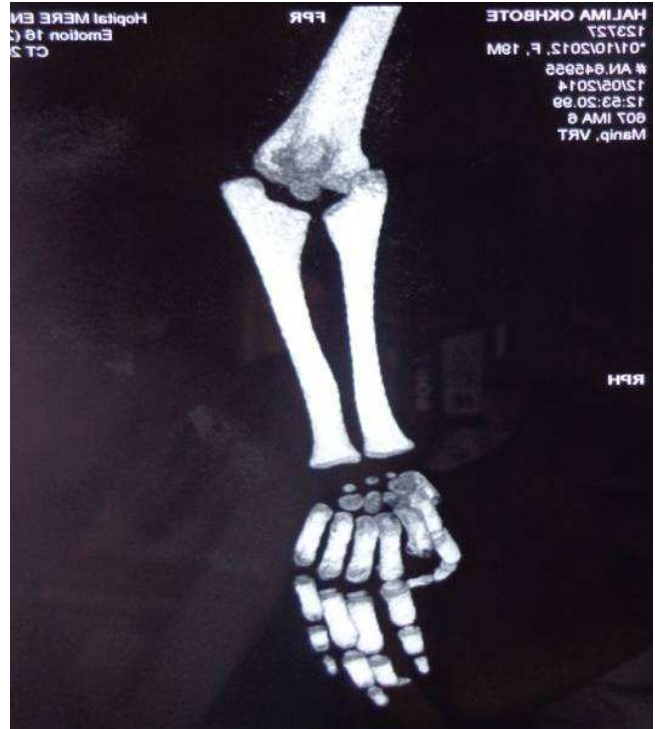### Iconography



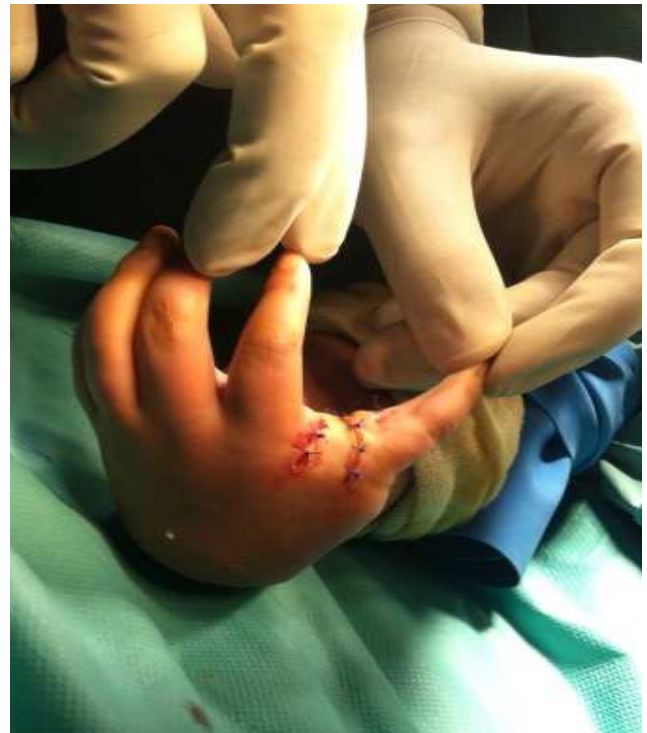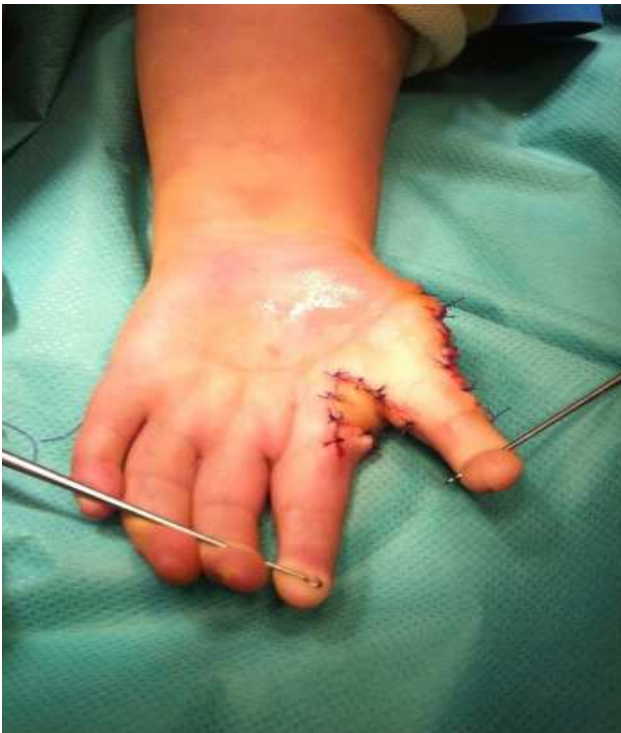**Fig.1** Polydactyly with 07 fingers



**Fig. 2 :** Radiographie montre la présence de 02 ulnas, 07 Métacarpiens et absence totale du



**Fig. 3 :** Duplicité ulnaire avec une bonne surface articulaire sur l'ulna interne, ulna externe bloquant la mobilité du coude



**Fig. 4:** Resection of the 7th finger and the pollicization of the 6th finger

## RESULT AND DISCUSSION

Ulnar duplication is a very rare congenital malformation of the upper limb, characterized by the association of ulna duplication, absence of the radius and polydactyly. About 20 isolated cases have been reported in the literature, they are often bilateral and more frequently involve the left upper limb [1,2]. She presents several difficulties concerning her medical and surgical treatment. The stiffness of the elbow and wrist remains a major problem, excision of supernumerary fingers and reconstruction of the thumb are the main lines of a treatment aimed at restoring the aesthetic and especially functional aspect of the hand. Another goal of treatment is to improve elbow flexion-extension and pronation-supination movements of the forearm [3,7]. The few publications on therapeutic modalities do not lead to a specific recommendation for the treatment of this anomaly [1,2,4]. A surgical treatment plan was proposed by Wood despite the different anatomical and clinical presentations of this malformation; the hand is treated by amputation of supernumerary fingers with pollicization of the first radial finger. The mobility of the wrist is improved by soft tissue movements by tendon release and transfer, and these movements are associated with resection of the first row of carp to increase stability [5]. According to most authors, elbow mobility and pronation-supination of the forearm can be treated by resection of the proximal end of the lateral ulna [1,5,6]. The results of these interventions are satisfactory from the aesthetic point of view, but are less functional.

## CONCLUSION

Ulnar duplication is a rare malformation of the upper limb. The surgical treatment remains complex, it is based on the release of the elbow, the wrist and the pollicization, which makes it a disappointing aspect of this malformation whose functional prognosis remains dark.

## REFERENCES

- [1] Harpf C, Hussl H. A case of mirror hand deformity with a 17-year-postoperative follow-up. Case report. *Scand J Plast Reconstr Hand Surg* **1999**;33:329—33.
- [2] Innis JW, Hedera P. Two patients with monomelic ulnar duplication with mirror hand polydactyly: segmental Laurin-Sandrow syndrome. *Am J Med Genet* **2004**;131A:77- 81.
- [3] S. El Hage, I. Ghanem, A. Megarbané, C. Razzouk, F. Dagher, K. Kharrat. Mirror hand deformity: A new phenotype. *Revue de chirurgie orthopédique et réparatrice de l'appareil moteur*. **2008** ; 94 : 174—178
- [4] Barton NJ, Buck-Gramcko D, Evans DM, Kleinert H, Semple C, Ulson H. Mirror hand treated by true pollicization. *J Hand Surg.* **1986**;11:320—36.
- [5] Wood VE. Ulnar dimelia (the mirror hand). In: Green DP, editor. *Operative hand surgery*. 2nd ed New York: Churchill-Livingstone; **1998**. p. 485—91.
- [6] Gorriz G. Ulnar dimélie – allimb without auteroposterior deffentiation. *J Hand Surg.* **1982** ; 7A :466-469
- [7] Yang SS, Jackson L, Green DW, et al, A rare variant of mirror hand : a case report. *J hand Surg.* **1996** ;21A : 1048-1051.